



# Physiologic Neuromuscular Dental Paradigm for the Diagnosis and Treatment of Temporomandibular Disorders

Prabu Raman, DDS, MICCMO, LVIM, FPFA, FACD

**ABSTRACT** Shifting from traditional anatomical/mechanistic models, the physiologic neuromuscular dentistry (PNMD) paradigm acknowledges the primacy of physiology in shaping and controlling anatomy in a functioning human body. Occlusal disharmony from mandibular discrepancy to cranium leads to temporomandibular disorders (TMD), which is a disease of musculoskeletal imbalance in the postural chain exceeding the individual's physiologic adaptive capacity. To diagnose optimal craniomandibular alignment, PNMD is guided by real-time objective physiologic data such as electromyography (EMG).

## AUTHOR


**Prabu Raman, DDS, MICCMO, LVIM, FPFA, FACD**, has practiced dentistry in Kansas City, Mo., since 1983, with an emphasis on neuromuscular dentistry/temporomandibular dysfunction, esthetic dentistry-complex restorative dentistry, neuromuscular functional orthodontics and sleep breathing disorders/oral appliance therapy. He is a fellow of the American College of Dentists and a fellow of the Pierre Fauchard Academy. Dr. Raman is

a past president of the International Association of Comprehensive Aesthetics, a past president of the Greater Kansas City Dental Society and serves as an HOD delegate, member of the Council on Dental Education and Licensure of the American Dental Association and as a trustee of the Missouri Dental Association. He earned his dental degree from the University of Missouri, Kansas City, School of Dentistry. *Conflict of Interest Disclosure: None reported.*

**T**he diagnosis and treatment of temporomandibular disorders (TMD) is the most confusing subject in dentistry. Many factors contribute to this confusion; chief among them is a simplistic view of this disease that relates it only to temporomandibular joints (TMJs) or attributes it to a single etiology. Another factor is the lack of TMD training in predoctoral dental education.

TMD encompasses a group of musculoskeletal and neuromuscular conditions that involve the masticatory system, the dentition (occlusion), the TMJs and all associated tissues. Quantum

improvements occur in any arena with a change in the basic paradigm.<sup>1</sup> The physiologic neuromuscular dentistry (PNMD) paradigm offers such a significant improvement in how the dental profession views and treats TMD. It acknowledges the primacy of physiology in shaping and controlling anatomy in a functioning human body. A guiding principle of PNMD is, "If it has been measured, it is a fact. If it has not been measured, it is an opinion." As such, physiologic data such as electromyography (EMG) of the jaw and neck muscles drive diagnostic and clinical decisions.

 Video for this article is available in the e-pub version of the *Journal*, available at [cda.org/apps](http://cda.org/apps).

The concepts and practice of neuromuscular dentistry go back to the 1950s and have since been improved considerably. These concepts are based on principles of physiology that earned Nobel prizes for their discoverers — Hill (glycolysis), Sherrington (reciprocal inhibition), Krebs (adenosine triphosphate [ATP] production), Eccles, Hodgkin and Huxley (action potential, myoneural junction, sliding muscle filaments) and Katz (muscle frequency and fatigue). Yet, many in our dental profession are still unfamiliar with PNMD concepts.

A dentist's duty is to relieve pain or adverse symptoms from which a patient seeks relief. Our patients are best served when TMD is viewed more comprehensively as a disease of musculoskeletal imbalance in the postural chain exceeding the individual's physiologic adaptive capacity.<sup>2</sup> This paradigm is more useful in the diagnosis and definitive treatment. Cranio-cervico-mandibular disorder (CCMD) would be a more accurate description of this disorder, but due to the historic use of the term, "TMD" is used in this paper.

Symptoms of TMD are so varied that it has been called the "great impostor." They include orofacial symptoms such as TMJ pain, articular disk displacement without reduction (closed lock), articular disk displacement with reduction (clicking) with or without pain, limited mandibular range of motion, facial pain, referred dental pain, excessive tooth structure loss, unexplained tooth mobility, unexplained bone loss and more. TMD symptoms also include headache, migraine,<sup>3</sup> earache,<sup>4,5</sup> ear congestion,<sup>6</sup> autophony, tinnitus,<sup>7</sup> vertigo,<sup>8</sup> cervical pain,<sup>9</sup> limited cervical range of motion, forward neck posture,<sup>10,11</sup> obstructive sleep disordered breathing,<sup>12</sup> fibromyalgia, swallowing disorders,<sup>13</sup> arm pain, paresthesia of fingertips,<sup>13</sup> back pain<sup>13</sup> and more. Other disorders

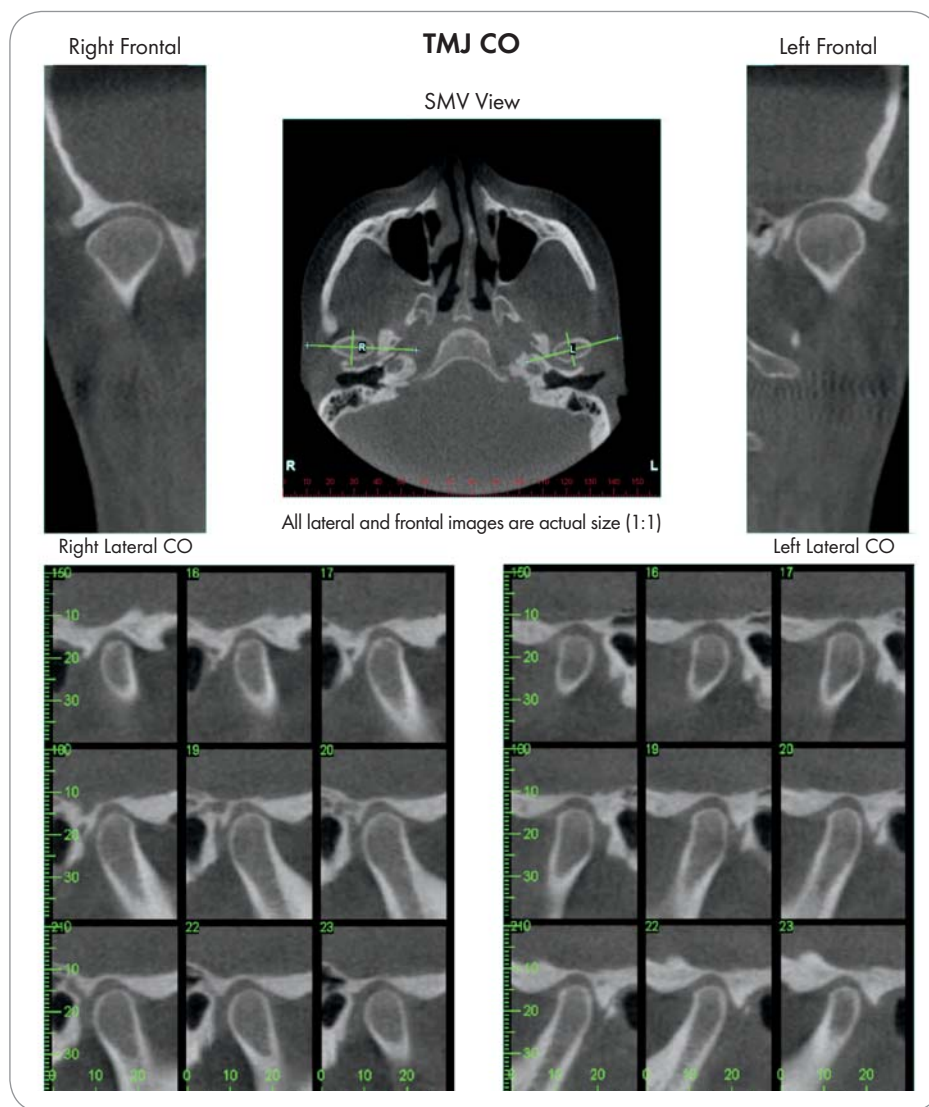
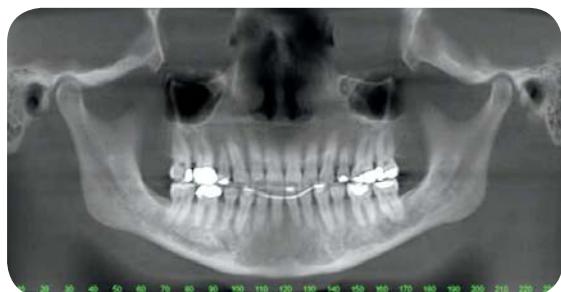

FIGURE 1. Pretreatment CT scan with teeth in occlusion – TMJ views coronal, axial and sagittal cuts.

of the body can cause some of the same symptoms, so a differential diagnosis must include TMD as a possible etiology, and other pathologies must be ruled out through appropriate tests or referrals.

The role of occlusion in the etiology of TMD has been widely documented in the dental literature.<sup>14</sup> Occlusal disharmony can result in hyperactivity and a disturbed pattern of muscle contractions leading to muscular pain and joint overload.<sup>15</sup> Palpation alone is a gross indicator at best and is subject to highly variable results among clinicians and to variability in the patient's tolerance. Therefore,

palpation alone is inadequate to provide the best possible clinical evaluation of the masticatory muscles.<sup>16</sup> Would we use subjective pain reported by a patient as the only criterion to evaluate the health of periodontium or of a carious lesion? A scientific and objective assessment of the masticatory muscles as part of the clinical examination is essential. Numerous studies have shown that the TMD patient population has elevated resting EMG activity and weak or asymmetrical functional EMG activity.<sup>17-19</sup> TMD patients frequently exhibit altered muscle activation patterns.



**FIGURE 2.** Pretreatment CT scan with teeth in occlusion – panoramic view.

The role of dentition is unique in the postural chain. No other joint has the end point that is as changeable as the dentition is to the TM joints. While much emphasis is placed on the actual interdigitation of teeth (occlusion), the effort needed by the mandibular posturing muscles to bring the teeth into occlusion is not usually measured. No matter how poorly aligned the teeth might be, the masticatory muscles will bring the teeth into occlusion so that we may chew, eat, swallow and survive. For example, if a poorly aligned door runs into the doorframe, it can still be forced to shut; but over time, this would lead to deterioration of the hinges. While no one will consider only the shut position of such a door and pronounce it as perfectly fitting, looking at the final occlusion alone ignores the muscular effort required to bring the mandible into that position. In this analogy, would the deterioration of the hinges be the only condition to qualify it as a problem? This is akin to those who would *not* consider a patient to have TMD if there are no overt signs of TMJ internal derangement or other joint symptoms. This analogy does not at all convey the complexity of the stomatognathic system.

Mandibular position and occlusion have a profound effect on postural stability.<sup>20,21</sup> Swallowing occurs hundreds of times a day.<sup>22</sup> When teeth contact, as in swallowing and chewing, mechanoreceptors in the periodontal ligaments are stimulated. These serve as an important peripheral afferent of proprioception for the central nervous system.<sup>23</sup> Forty percent of the postural data that the brain receives is from the position of the mandible in

space.<sup>24</sup> Mandibular posture and cervical posture are functionally connected;<sup>25,26</sup> as such, mandibular posture affects upper cervical posture.<sup>27,28</sup> The alignment of these craniocervical vertebrae also affects the lumen of the spinal canal at this critical level, as well as the flow characteristics through the vertebral arteries. It even impacts the tension on the recently discovered myodural junction between dura mater and the rectus capitus posterior minor muscle,<sup>29</sup> which could explain cervicogenic headaches. TMJs are functionally related to the atlanto-occipital joints,<sup>30</sup> which in turn have a profound impact on the central nervous system.<sup>31</sup> Cervical posture affects the lumbar and overall posture.<sup>32</sup> Based on these facts, it is clear that the impact of dental occlusion on the function of the human body is quite profound.

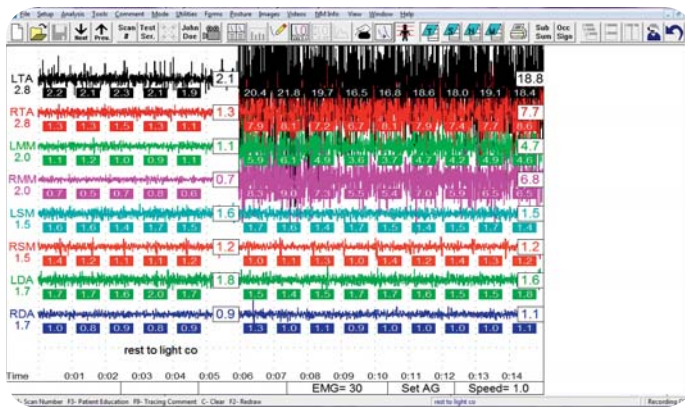
TMD sufferers do not want to be medicated for the rest of their lives to only dull their symptoms through a medical pain management paradigm. Many consider these medications to be ineffective or the side effects unacceptable. Most find their condition progressing from mild to worse and sometimes to disabling. While they experience unrelenting pain or discomfort, many patients do not show radiological evidence of breakdown in their TMJ for years or show external signs such as hemorrhage or edema. This is a helpless position to be in, to feel the pain but see no end in sight. However, EMG studies are valuable in objectively revealing the dysfunctional physiology of the masticatory muscles.

To illustrate this point, the author presents the case history of Dana P.

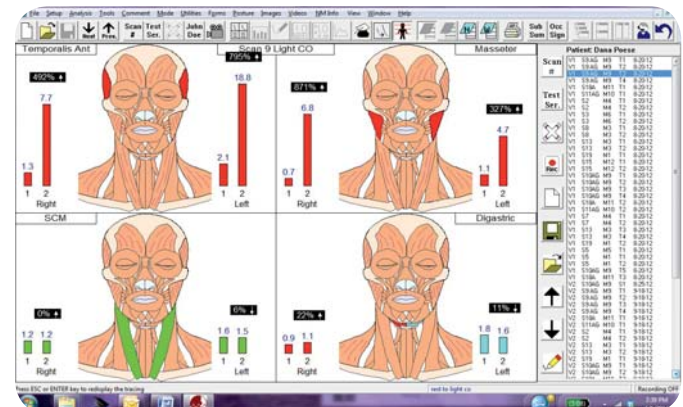
After all, intellectual discussions of philosophical differences do not interest dentists in clinical practice as much as the application of such a philosophy in helping an actual patient. Dana, a 49-year-old female small business owner who was in good health except for a 15-year history of weekly migraines, presented for a TMD evaluation. Her general dentist, an oral surgeon who evaluated her TMJ and the orthodontist who treated her as an adult to achieve better occlusion had all concluded that she had no “TMJ disorder.” She had been diagnosed with migraines by a neurologist and had been on various migraine, nausea and muscle relaxant medications for maintenance and to abort migraines. Otolaryngologists, allergists, pain management specialists, three chiropractors, a physical therapist, four neurologists and numerous massage therapists had treated her over the 15 years. Yet she also had back pain, neck pain, pain behind the eyes, shoulder pain, etc. When she took Zomig to abort a migraine onset, she would have to lie down in a dark room for a day and it often took another day for her to feel normal again. Because she had two to three migraine attacks a week, most days she was either in bed with a migraine or recovering from one.

Oral examination of the hard and soft tissue was done. Findings were:

- Teeth Nos. 1, 5, 12, 16, 17, 21, 28 and 32 had been removed for orthodontia.
- Bilateral mandibular buccal exostoses, bilateral antegonial mandibular notching and a scalloped tongue were noted.
- Mandibular range of motion: vertical = 54 mm, right lateral excursion = 11 mm, left lateral excursion = 9 mm, protrusion = 10 mm.
- Upper cervical rotation range of motion was measured: 65 degrees to the right side, 60 degrees to the left side.
- Blood pressure: 122/77, pO<sub>2</sub>: 99% and pulse rate: 62 were



**FIGURE 3.** Pretreatment sEMG scan of mandibular and cervical posture muscles at rest versus at light occlusion. LTA = left temporalis anterior, LMM = left medial masseter, RSM = right sternocleidomastoid and RDA = right digastric anterior.



**FIGURE 4.** Comparison of muscle recruitment at rest versus effort needed to bring teeth into just light occlusion prior to chewing. RTA and LTA posture the mandible and bring it through space into occlusion.

recorded with pulse oximetry.

- Palpation of TMJ, jaw and cervical muscles was performed and recorded.
- Severe tenderness was noted at left shoulder trapezius and bilateral lateral pterygoids; moderate tenderness was noted at bilateral medial pterygoids, right posterior scalene and bilateral stylomandibular ligaments; mild tenderness was noted at left temporal tendon, right levator scapula, right neck trapezius, left posterior scalene, right anterior scalene, right sternocleidomastoid muscle (SCM), bilateral occipital, bilateral middle scalenes, bilateral posterior TMJ space and bilateral joint capsules.

Cone beam CT evaluation of the TMJs was within normal limits with slight reduction of joint space. It was negative for condylar deformation or deterioration (**FIGURES 1 and 2**).

A Myotronics K7 evaluation system was utilized. The patient's resting EMG, shown on the left half of the image, was within the norms noted on the left margin. However, the effort it took for her temporalis muscles just to bring the teeth into occlusion, shown on the right half of the image, increased 5X on the left and 8X on the right side compared to resting posture (**FIGURES 3 and 4**).

Her cranial nerves V, VII and XII (trigeminal, facial and spinal accessory

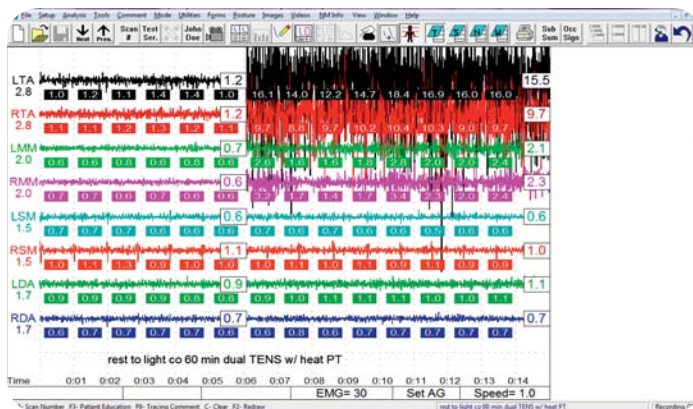
nerves) were pulsed for 60 minutes by ultra-low-frequency transcutaneous electroneural stimulation (ULF-TENS). Every muscle innervated by these nerves was pulsed for 0.5 second every 1.5 seconds so they would contract and relax, essentially massaging each of these muscles to improve oxygenated blood flow, eliminating waste products such as lactic acid from the muscles to reestablish a biochemical and physiologic optimum. A repeat EMG showed even lower recruitment of these muscles, denoting relaxed muscles. From this optimal physiologic condition, the true magnitude of the mandibular discrepancy was revealed when the patient brought her teeth into light occlusion requiring 7X on the right side and 12X on the left temporalis (**FIGURES 5 and 6**).

Once the 3-D relationship of the mandible to maxilla was diagnosed, a temporary anatomic fixed orthotic was constructed of Integrity resin (DENTSPLY, Milford, Del.) on the mandibular arch to allow for physiologic economy of the posturing muscles. The patient functioned with this fixed orthotic that she could not remove but that could be removed by the dentist if the treatment was unsuccessful in symptom resolution. At a follow-up visit seven days after delivery, the mandibular function was again objectively evaluated and coronoplastied. The

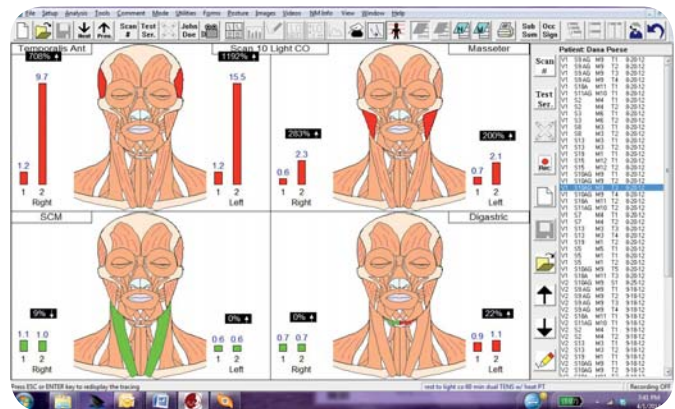
same act of bringing the teeth into occlusion was almost effortless with the orthotic (**FIGURES 7 and 8**).

While this objective measure of improvement is encouraging, the most important measure is that all of Dana's symptoms resolved 70 percent within 30 days, far exceeding her expectations. Therefore, she chose the option of orthodontically moving her teeth, guided by the physiologic metrics to permanently change her mandibular alignment. One year later, she is currently undergoing physiologic neuromuscular orthodontics and remains 90 percent symptom-free. The improvement in Dana's quality of life and that of her family is immeasurable, according to her and her husband.

Dentists who choose to treat TMD patients should acknowledge that TMD is multifactorial.<sup>33-36</sup> They should use objective measurements of physiology<sup>37</sup> to supplement anatomical data such as radiographic imaging and subjective reports in the diagnosis and treatment. TMJ radiographic imaging does not make a diagnosis of etiology in and of itself. Qualified medical professionals interpret imaging records and those data facilitate the overall diagnosis. Similarly, surface EMG studies provide objective clinical information about masticatory muscle status, which a properly trained dentist interprets to aid in his or her



**FIGURE 5.** Post ULF-TENS treatment sEMG scan of mandibular and cervical posture muscles at rest versus at light occlusion reveals the actual level of mandibular discrepancy to maxilla.



**FIGURE 6.** Comparison of muscle recruitment at rest versus effort needed to just bring teeth into light occlusion prior to chewing.

diagnosis. The bioelectronic devices commonly known as neuromuscular measurement devices are used to provide the diagnosing clinician with much expanded, precise, objective measurements and clinical information to reach an accurate diagnosis. The role of these instruments in reliably documenting and providing objective data is well documented in numerous studies.<sup>38-40</sup>

As dentists, our training and license to practice limit us to the orofacial region. At the outset, it is necessary to determine whether the primary etiology of the patient's complaints is related to a discrepancy of mandibular posture. If so, a comprehensive gathering of data is needed to facilitate an accurate diagnosis. These may include the following:

- Comprehensive history, including medical and dental history.
- Thorough examination of the dentition and periodontium.
- Diagnostic photographs of the dentition, face and posture.
- Palpation of the muscles of mastication, TMJs and cervical muscles.
- Range of motion records of mandible and upper cervical spine.<sup>41</sup>
- Surface electromyographic (sEMG) studies of muscles of mandibular and cervical posture.<sup>42</sup> These may include sEMG measurements of muscles of mandibular posture at rest,<sup>43,44</sup> with

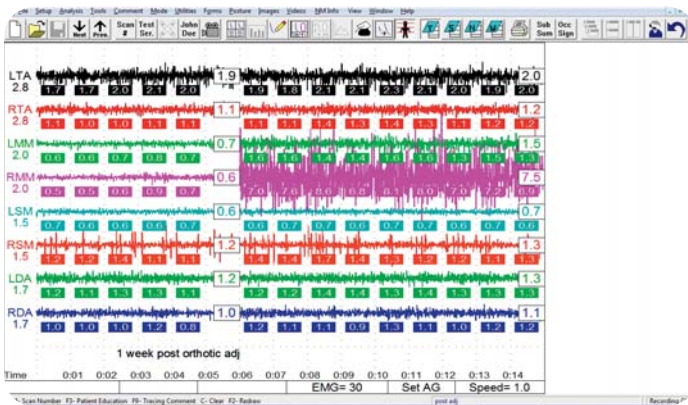
teeth in light habitual occlusion,<sup>45</sup> maximum clenching<sup>46</sup> and contraction frequency of muscles that indicate muscle fiber types and fatigue levels.<sup>47</sup> The utility and reliability of sEMG is well established in research literature.<sup>48-50</sup>

- Computerized jaw tracking studies of mandibular movement.<sup>51</sup>
- Electrosonography (ESG) recordings of TMJ sounds during function.<sup>52</sup>
- Cone beam CT views or corrected tomograms of the TMJs in habitual occlusion, maximal opening and maximal protrusion.
- Static posture and gait analyses to identify postural compensations.
- ULF-TENS of muscles of mastication and cervical posture through neurally mediated pulses.<sup>53-57</sup>
- Determination of the physiologic neuromuscular mandibular position within a neutral zone when muscles of mastication and cervical posture are optimally unstrained.<sup>58</sup> Objective, real-time EMG measurements of the posture muscles guide the clinician in diagnosing this position.<sup>59</sup> There is universal agreement on comfortable, unstrained masticatory muscles as a requisite for a healthy stomatognathic system. PNMD protocols actually measure physiologic data to confirm this, rather than just relying on subjective measures. The discrepancy between

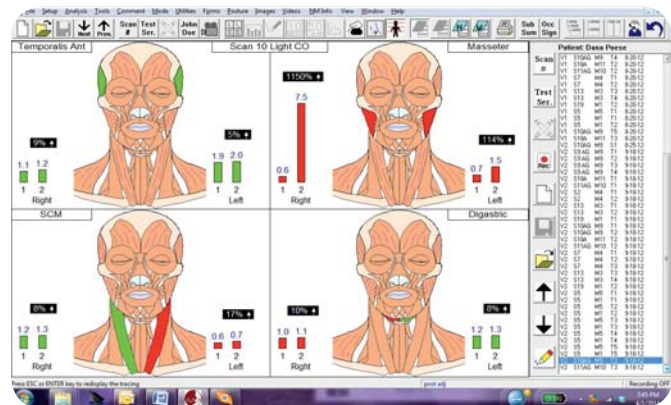
the mandibular position of presenting habitual occlusion and the physiologic neuromuscular mandibular position is the starting point of therapy.<sup>60</sup>

A neuromuscular dental treatment plan requires minimal or no treatment when the dentist's diagnosis so indicates. Provisional, reversible treatment that accommodates chewing and speaking is used first to confirm the efficacy of therapy, validate the planned treatment and to further refine the mandibular position before any permanent alteration of the teeth is done. Because mandibular posture is a function of the overall posture, as the posture improves, the mandibular posture may change as well until stability is achieved. The patient and dentist have the option of discontinuing orthotic therapy if there is inadequate improvement. Objective measures, similar to the pretreatment diagnostic series, are used to evaluate progress. Treatment progress needs to be evaluated partly through subjective reports, as has been done traditionally. However, because there are inherent inaccuracies involved in subjective reports, objective measures are needed, as well. This is akin to a physician using electrocardiogram recordings or blood pressure readings for diagnosis as well as evaluating the efficacy of treatment and not just relying on how the patient feels.

Only when there is substantial improvement in both subjective and



**FIGURE 7.** One week post PNMD fixed orthotic treatment sEMG scan of posture muscles at rest versus effortless occlusion proves that the mandibular discrepancy to maxilla has been corrected through the PNMD orthotic.



**FIGURE 8.** Comparison of muscle recruitment at rest versus effort needed to bring teeth into light occlusion prior to chewing shows that temporalis anterior muscles needed little effort. This correlates with symptom resolution.

objective measurements of treatment progress, thus proving the validity of the craniomandibular position, should any stabilizing steps that involve irreversible changes even be considered.<sup>61</sup> These include orthodontic movement of teeth, restorative treatment of some or all teeth and prosthetic replacement of missing teeth. No matter which option is chosen, objective data are used as a guide by the treating dentist to either replicate or further improve the mandibular position previously proven by the reversible orthotic therapy. Each of these options has corresponding consequences. It is the treating dentist's responsibility to educate the patient on these consequences. Ultimately, it is the patient's prerogative to make the decision on the options, including the option of no treatment, once all the consequences of each option are well understood. In this manner, any choice the patient makes is an informed decision.<sup>62</sup>

In discussions of evidence-based dentistry (EBD), the greatest importance is placed on literature citations. As defined at the 2008 ADA Evidenced-based Dentistry conference, "Evidence-based dentistry is an approach to oral health care that requires the judicious integration of systematic assessments of clinically relevant scientific evidence, relating to the patient's oral and medical condition and history, with the dentist's clinical expertise and the patient's

treatment needs and preferences."<sup>63</sup> A dentist's clinical expertise and a patient's treatment needs and preferences are equally as valid as literature support. In their *JADA* editorial, Glick and Meyer acknowledge, "In reality, a lack of clinical research or insufficient clinical evidence is the rule rather than the exception in dentistry and medicine." They also state, "Scientific plausibility — or 'prior probability' — also must be considered. Good science accounts for all relevant evidence, including prior probabilities, as building blocks for new data. These prior probabilities may include the experience of having previously adhered to a specific treatment approach and ... health care providers must continually seek to improve the quality of patient care through sound professional judgment based on provider experience, expertise and clinically relevant research."<sup>64</sup> Neuromuscular dentists have the necessary expertise and the experience of thousands of patients whose TMD symptoms were successfully resolved through a comprehensive approach for evaluation and treatment.

PNMD protocols are indeed guided by evidence-based dentistry<sup>65</sup> in line with the ADA's position of considering the clinical expertise of thousands of private-practice dentists around the world who successfully treat TMD patients daily. Even more important, this approach considers

the treatment needs and preferences of patients who choose treatment options after being fully informed of the consequences of all options — including letting their disease continue without any intervention. All caring practitioners can support this approach that respects the patients who seek our care. ■

#### REFERENCES

1. Covey SR. *The 7 Habits of Highly Effective People*.
2. Cuccia A, Caradonna C. The relationship between the stomatognathic system and body posture. *Clinics* 2009;64(1):61-6.
3. Milanov I, Bogdanova D. Trigemino-cervical reflex in patients with headache. *Cephalalgia* 2003 Feb;23(1):35-8.
4. Kim DS, Cheang P, Dover S, Drake-Lee AB. Dental otalgia. *J Laryngol Otol* 2007 Dec;121(12):1129-34.
5. Cooper BC. Recognition of craniomandibular disorders. *Otolaryngol Clin North Am* 1992 Aug;25(4):867-87.
6. Bjorne A, Agerberg G. Reduction in sick leave and costs to society of patients with Meniere's disease after treatment of temporomandibular and cervical spine disorders: a controlled six-year cost-benefit study. *Cranio* 2003 Apr;21(2):136-43.
7. Bjorne A, Berven A, Agerberg G. Cervical signs and symptoms in patients with Meniere's disease: a controlled study. *Cranio* 1998 Jul;16(3):194-202.
8. Bjorne A, Agerberg G. Symptom relief after treatment of temporomandibular and cervical spine disorders in patients with Meniere's disease: a three-year follow-up. *Cranio* 2003 Jan;21(1):50-60.
9. Visscher CM, Lobbezoo F, de Boer W, van der Zaag J, Naeije M. Prevalence of cervical spinal pain in craniomandibular pain patients. *Eur J Oral Sci* 2001 Apr;109(2):76-80.
10. D'Attilio M, Epifania E, Ciuffolo F, Salini V, Filippi MR, Dolci M, Festa F, Tecco S. Cervical lordosis angle measured on lateral cephalograms; findings in skeletal class II female subjects with and without TMD: a cross sectional study. *Cranio* 2004 Jan;22(1):27-44.
11. Makofsky HW. "The influence of forward head posture on dental occlusion." *Cranio* 2000 Jan;18(1):30-9.
12. Cunali PA, Almeida FR, Santos CD, Valdrighi NY, Nascimento LS, Dal'Fabbro C, Tufik S, Bittencourt LR. Prevalence of temporomandibular disorders in obstructive sleep apnea

- patients referred for oral appliance therapy. *Orofac Pain* 2009 Fall;23(4):339-44.
13. Simons DG, Travell JG, Simons LS. *Myofascial Pain and Dysfunction*. vol. 1. 2nd ed. Williams & Wilkins. p. 368. p. 505. p. 292.
  14. Čelić R, Kraljević K, Kraljević S, Badel T, Pandurić J. The Correlation Between Temporomandibular Disorders and Morphological Occlusion. *Acta Stomatol Croat* 2000;34(1).
  15. Fushima K, Inui M, Sato S. Dental asymmetry in temporomandibular disorders. *J Oral Rehabil* 1999;26(9):752-756.
  16. Sato H, Matsuguma T, et al. Deformation displacement of posterior digastric and sternocleidomastoid muscles during posterior digastric muscle palpation using magnetic resonance imaging and image processing procedure. *J Oral Rehabil* volume 29, issue 9, pages 884–885, September 2002.
  17. Tartaglia GM, Moreira Rodrigues da Silva MA, Bottini S, Sforza C, Ferrario VF. Masticatory muscle activity during maximum voluntary clench in different research diagnostic criteria for temporomandibular disorders (RDC/TMD) groups. *Man Ther* 2008;13(5):434-440.
  18. Tecco S, Telè S, D'Attilio M, Perillo L, Festa F. Surface electromyographic patterns of masticatory, neck, and trunk muscles in temporomandibular joint dysfunction patients undergoing anterior repositioning splint therapy. *Eur J Orthod* 2008;30(6):592-597.
  19. Santana-Mora, U, Cudeiro J, Mora-Bermudez MJ, Rilo-Pousa B, Ferreira-Pinho JC, Otero-Cepeda JL, Santana-Penin U. Changes in EMG activity during clenching in chronic pain patients with unilateral temporomandibular disorders. *J Electromyogr Kinesiol* 2009;19(6):e543-549.
  20. Munhoz WC, Marques AP, de Siqueira JT. Evaluation of body posture in individuals with internal temporomandibular joint derangement. *Cranio* 2005 Oct;23(4):269-77.
  21. Gangloff P, Louis JP, Perrin PP. "Dental occlusion modifies gaze and posture stabilization in human subjects." *Neurosci Lett* 2000 Nov 3;293(3):203-6.
  22. Lear CSC, Flanagan JB, Moorrees, CFA. The frequency of deglutition in man. *Arch Oral Biol* 10:83-99, 1965.
  23. Dessem D, Donga R, Luo P. Primary- and secondary-like jaw-muscle spindle afferents have characteristic topographic distributions. *J Neurophysiol* 1997 Jun;77(6):2925-44.
  24. Beck JL. Lecture at Parkinson's Resource Organization's symposium, January 2011.
  25. Santander H, Miralles R, Jimenez A, Zuniga C, Rocabado M, Moya H. Influence of stabilization occlusal splint on craniocervical relationships. Part II Electromyographic analysis. *Cranio* 1994 Oct; 12 (4):227-33.
  26. Olmos SR, Kritz-Silverstein D, Halligan W, Silverstein ST. The effect of condyle fossa relationships on head posture. *Cranio* 2005 Jan;23(1):48-52. TMJ Therapy Centre, La Mesa, CA 91942, USA.
  27. Ferrario VF, Sforza C, Dellavia C, Tartaglia GM. Evidence of an influence of asymmetrical occlusal interferences on the activity of the sternocleidomastoid muscle. *J Oral Rehabil* 2003, vol. 30, no. 1. pp. 34-40.
  28. Shimazaki T, Motoyoshi M, Hosoi K, Namura S. The effect of occlusal alteration and masticatory imbalance on the cervical spine. *Eur J Orthod* 2003 Oct;25(5):457-63.
  29. Hack GD, Hallgren RC. Chronic headache relief after section of suboccipital muscle dural connections: A care report. *Headache* vol. 44 no. 1, Jan 2004, pp. 84-89 (6).
  30. Thomas NR, Dickerson WG, Thomas TD, Davies P. The Relationship Between the Upper Cervical Complex and the TMJ Joint in TMD and its Treatment Correction. *LVI Visions* 2009 – Jan: 60-68.

## Other Authors' Critiques of Dr. Raman's Paper

### Dr. Friction

*Physiologic Neuromuscular Dentistry Strategy*. Dr. Raman discusses the use of objective physiologic data such as surface electromyography (EMG) and jaw tracking to determine whether occlusal disharmony is causing muscle hyperactivity in the masticatory system. To illustrate his point, he presents a case showing that muscle activity was reduced when a permanent full-time occlusal splint was used. At 30-day follow-up, 70 percent of the patient's symptoms were resolved. Thus, he recommended that the patient redo her orthodontic care to move her teeth and jaw to a new "physiologic" position as determined by surface electromyography. The paper states that because this approach uses objective equipment such as EMG and jaw tracking, it follows evidence-based dentistry. Unfortunately, the paper does not review any scientific evidence related to the reliability and validity of these diagnostic tests nor the results of any placebo-controlled, randomized controlled trial evaluating the efficacy of this approach. Furthermore, the possible adverse events of this approach are not discussed.

*Editor's note: See Dr. Friction's general comments and conclusion on page 545.*

### Dr. Simmons

Dr. Raman's manuscript is supportive of neuromuscular dentistry concepts. Muscle dysfunction concepts and management by transcutaneous electroneural stimulation (TENS) are described. A mandibular rest position is achieved and utilized as a dental occlusal treatment position for relief of pain and dysfunction of the masticatory muscles.

*Page 563 "As such, physiologic data such as electromyography (EMG) of the jaw and neck muscles drive diagnostic and clinical decisions."*

Muscle pain, one of the symptoms associated with TMD, has not been shown to be consistently enough reflected in EMG data (J. Radke, president, BioResearch Inc., written communication, February 2011).<sup>1</sup> Internal derangement of the TMJ does not universally alter muscle function in a predictable way such that EMG data can consistently detect this condition (J. Radke, president, BioResearch Inc., written communication, February 2011).<sup>1</sup> TMJ surface EMG in clinical use has little value in testing for the presence or absence of specific masticatory muscle and TMJ disk displacement disorders.<sup>2,4</sup> There is very little consensus about the use of EMG in the diagnosis and treatment of some TMDs.

*Page 564. "So palpation is inadequate to provide the best possible clinical evaluation of the masticatory muscles."*

On page 565, Dr. Raman uses detailed palpation of TMJ, jaw and cervical muscles in his example of a patient examination. On page 567, Dr. Raman lists "Palpation of the muscles of mastication, TM joints and cervical muscles" in his gathering of data for a diagnosis.

*Page 564. "TMD patients frequently exhibit altered muscle activation patterns."*

Muscles do cause most of the pain in a TMD patient, but the cause of the disorder is usually not the muscles; it is the underlying injury to the TMJ or neck vertebrae. Cyriax believes that muscles are the alarm that tells us there is something wrong in the neighborhood.<sup>5</sup> The question that should be asked is, "Why are these muscles in involuntary contraction?" Isberg believes that chronic contraction in the muscles of mastication may be caused by a displaced TMJ disk.<sup>6</sup> Cyriax believes that if one can treat the joint's arthritis and/or internal derangement, the muscle contractions resolve on their own.<sup>5</sup> Neuromuscular dentistry seems to be treating the secondary, not the primary, cause of a patient's pain and dysfunction.

CONTINUES IN SIDEBAR ON 570

## OTHER AUTHORS' CRITIQUES, CONTINUED FROM 569

How does the neuromuscular dentist treat an acute disk displacement without reduction or intermittent acute displacement without reduction? If a practitioner is solely focused on the muscles, how is a TMJ internal derangement treated?

Care of the TMD patient is broken down into assessment, diagnosis and management.<sup>7</sup> Diagnostic tests, beyond range of motion, anatomic site palpation and diagnostic anesthetic blocks, have a minimal role in determining who needs TMD care.<sup>1</sup> The diagnosis of the TMD patient is properly based upon history (82 percent); then confidence in the diagnosis is added with examination (9 percent) and testing (9 percent).<sup>8</sup>

This paper is supportive of neuromuscular dentistry as the method of diagnosing and treating TMDs. Any significant opening of the mouth through muscle pulsing with TENS or other method causes anterior repositioning of the mandibular condyles in their fossae. The reviewing author believes that this technique accomplished its goals because of the underlying repositioning of the condyles to a more physiologic orthopedic position in the fossae. This anterior repositioning of the condyles may have caused the muscles associated with the joint to sense that the joints were more normal and therefore the muscles to reduce in contraction and the pain and dysfunction diminished.

I would like to thank Dr. Raman for participating in this journalistic endeavor. His patients appreciate his care in relieving their pain and dysfunction.

1. Simmons HC 3rd. A critical review of Dr. Charles S. Greene's article titled "Managing the Care of Patients with Temporomandibular Disorders: a new Guideline for Care" and a revision of the American Association for Dental Research's 1996 policy statement on temporomandibular disorders, approved by the AADR Council in March 2010, published in the *Journal of the American Dental Association* September 2010. *Cranio* 2012;30(1):9-24.
2. Lund JP, Widmer CG, Feine JS. Validity of diagnostic and monitoring tests used for temporomandibular disorders. *J Dent Res* 1995;74(4):1133-43.
3. Lund JP, Widmer CG. Evaluation of the use of surface electromyography in the diagnosis, documentation, and treatment of dental patients. *J Craniomandib Disord* 1989;3(3):125-37.
4. Cecere F, Ruf S, Pancherz H. Is quantitative electromyography reliable? *J Orofac Pain* 1996;10(1):38-47.
5. Cyriax J. *Diagnosis of Soft Tissue Lesions*. 8th ed: Bailliere Tindall; 1982.
6. Isberg A, Widmalm SE, Ivarsson R. Clinical, radiographic and electromyographic study of patients with internal derangement of the temporomandibular joint. *Am J Orthod* 1985;88(6):453-60.
7. Simmons HC. *Craniofacial Pain: A Handbook for Assessment, Diagnosis and Management*. Chattanooga: Chroma Inc.; 2009.
8. Zakrzewska JM. History Taking. In: Zakrzewska JM, Harrison SD, editors. *Assessment and Management of Orofacial Pain*. 1st ed. London: Elsevier; 2002.

## Dr. Gelb

The physiologic neuromuscular dental paradigm puts a premium on the muscular and reduces the significance of the TMJ, articular disk and airway.

The TMJ is objectively measured with MRI and cone beam CT and the airway with a polysomnogram and home sleep testing. The physiology of the airway affects the growth and development of the face and with it the mandible and TMJ.

Dr. Raman states, "Occlusal disharmony can result in hyperactivity and a disturbed pattern of muscle contractions, leading to muscular pain and joint overload." AC looks at airway first, TMJ and myofascial second and occlusion third. Occlusal disharmony is not the driver in AC TMJ philosophy.

When considering the actual interdigitation of the teeth, it is not "the effort" needed by the muscles to bring the teeth into occlusion that is crucial, but more important, the efforts of the individual to breathe and maintain an open airway that affects the autonomic nervous system, oxidative stress and systemic inflammation.

31. Bakris G, Dickholtz M, et al. Atlas vertebra realignment and achievement of arterial pressure goal in hypertensive patients: a pilot study. *J Hum Hypertens* 2007; 1-6.
32. Schieppati M, Nardone A, Schmid M. Neck muscle fatigue affects postural control in man. *Neuroscience* 2003;121(2):277-85.
33. Vignolo V, Vedolin GM, de Araujo Cdos R, Rodrigues Conti PC. Influence of the menstrual cycle on the pressure pain threshold of masticatory muscles in patients with masticatory myofascial pain. *Oral Surg Oral Med Oral Pathol Oral Radiol Endod* 2008 Mar;105(3):308-15.
34. Benoliel R, Sharav Y. Craniofacial pain of myofascial origin: temporomandibular pain & tension-type headache. *Compend Contin Educ Dent* 1998 Jul;19(7):701-4, 706, 708-10 passim; quiz 722.
35. Nowlin TP, Nowlin JH. Examination and occlusal analysis of the masticatory system. *Dent Clin North Am* 1995 Apr;39(2):379-401.
36. Lima AF, Cavalcanti AN, Martins LR, Marchi GM. Occlusal interferences: how can this concept influence the clinical practice? *Eur J Dent* 2010 October; 4(4): 487-491.
37. Cooper BC. The role of bioelectronic instruments in documenting and managing temporomandibular disorders. *J Am Dent Assoc* 1996 Nov;127(11):1611-4.
38. Hickman DM, Cramer R. The effect of different condylar positions on masticatory muscle electromyographic activity in humans. *Oral Surg Oral Med Oral Pathol Oral Radiol Endod* 1998; 86(1):2-3.
39. Hugger A, Hugger S, Schindler H. Surface electromyography of the masticatory muscles for application in dental practice. Current evidence and future developments. *Int J Comput Dent* 2008; 11(2):81-106.
40. Cooper B, Kleinberg I. Establishment of a temporomandibular physiological state with neuromuscular orthosis treatment affects reduction of TMD symptoms in 313 patients. *Cranio* 2008;26(2) 104-117.
41. D'Attilio M, Epifania E, Ciuffolo F, Salini V, Filippi MR, Dolci M, Festa F, Tecco S. Cervical lordosis angle measured on lateral cephalograms; findings in skeletal class II female subjects with and without TMD: a cross sectional study. *Cranio* 2004 Jan;22(1):27-44.
42. Jankelson RR, Adib F. Literature Review of Scientific Studies Supporting the Efficacy of Surface Electromyography, Low Frequency TENS, and Mandibular Tracking for Diagnosis and Treatment of TMD. *Myotronics* 1995.
43. Riise C, Sheikholeslam A. The influence of experimental interfering occlusal contacts on the postural activity of the anterior temporal and masseter muscles in young adults. *J Oral Rehabil* 1982 Sep;9(5):419-25.
44. Biasotto-Gonzalez DA, Fausto Bérzin F. Electromyographic study of patients with masticatory muscles disorders, physiotherapeutic treatment. *Braz J Oral Sci* vol. 3, num. 10, 2005, pp. 516-521 *Braz J Oral Sci*, vol. 3, no. 10, July/September 2004, pp. 516-521.
45. Li J, Jiang T, Feng H, Wang K, Zhang Z, Ishikawa T. The electromyographic activity of masseter and anterior temporalis during orofacial symptoms induced by experimental occlusal highspot. *J Oral Rehabil* 2008 Feb;35(2):79-87.
46. Sheikholeslam A, Riise C. Influence of experimental interfering occlusal contacts on the activity of the anterior temporal and masseter muscles during submaximal and maximal bite in the intercuspal position. *J Oral Rehabil* 1983 May;10(3):207-14.
47. Thomas NR. The Effect of Fatigue and TENS on the EMG Mean

CONTINUES IN SIDEBAR ON 571



Power Frequency. 1990 *Frontiers of Physiology* (Basel Karger) vol. 7, pp. 162-170.

48. Castrolforio T, Icardi K, Torsello F, Deregibus A, Debernardi C, Bracco P. Reproducibility of surface EMG in the human masseter and anterior temporalis muscle areas. *Cranio* 2005;23(2): 130-137.

49. Castrolforio T, Icardi K, Becchino B, Merlo E, Debernardi C, Bracco P, Farina D. Reproducibility of surface EMG variables in isometric sub-maximal contractions of jaw elevator muscles. *J Electromyogr Kinesiol* 2006;16(5):498-505. Epub 2005 Nov. 15.

50. Castrolforio T, Bracco P, Farina D. Surface electromyography in the assessment of jaw elevator muscles. *J Oral Rehabil* 2008;35(8):638-645. Epub 2008 May 9.

51. Dickerson W, Chan C, Mazzocco M. The Scientific Approach to Neuromuscular Occlusion. *Signature* vol. 7, no. 2, pp. 14-17. 2000.

52. Elfving L, Helkimo M, Magnusson T. Prevalence of different temporomandibular joint sounds, with emphasis on disc-displacement, in patients with temporomandibular disorders and controls. *Swed Dent J* 2002;26(1):9-19.

53. Fujii H, Mitani H. Reflex Responses of the Masseter and Temporal Muscles in Man. *J Dent Res* September-October 1973 vol. 52 no. 5.

54. McMillan AS, Jablonski NG, McMillan DR. The position and branching pattern of the facial nerve and their effect on transcutaneous electrical stimulation in the orofacial region. *Oral Surg Oral Med Oral Pathol* 1987 May;63(5):539-41.

55. Jankelson B, Spark S, Crane P. "Neural conduction of the myo-monitor stimulus: A quantitative analysis." *J Prosthet Dent* vol. 34 no. 3, pp. 245-253 September 1975.

56. Thomas, N. (1990) *Front Oral Physiol Basel Karger* vol. 7; pp.162-170.

57. Raman P. Neurally mediated ULF-TENS to relax cervical and upper thoracic musculature as an aid to obtaining improved cervical posture and Mandibular posture. The Application of the Principles of Neuromuscular Dentistry to Clinical Practice. *Anthology* vol. IX, ICCMO pp. 77-85.

58. Lynn J, Mazzocco M, Miloser S, Zullo T. Diagnosis and Treatment of Craniocervical Pain and Headache based on Neuromuscular Parameters. *Amer J Pain Management* 1992;2(3):143-151.

59. Ceneviz C, Mehta NR, Forgione A, Sands MJ, Abdallah EF, Lobo Lobo S, Mavroudi S. The immediate effect of changing mandibular position on the EMG activity of the masseter, temporalis, sternoideomastoid, and trapezius muscles. *Cranio* 2006 Oct;24(4):237-44.

60. Lynn J, Mazzocco MW, Miloser SJ, Zullo T. Diagnosis & treatment of craniocervical pain and headache based on neuromuscular parameters. *Amer J Pain Management* vol. 2 no. 3 pp. 143-151. 1992.

61. American Dental Association Dental practice parameters – TMD adopted 1996 revised 1997.

62. Glick M. Informed consent: a delicate balance. *J Am Dent Assoc* 2006 Aug;137(8):1060, 1062, 1064.

63. American Dental Association – EBD Conference, May 2-4, 2008.

64. Glick M, Meyer DM. Evidence or science based? There is a time for every purpose. Editorial. *J Am Dent Assoc* 142(1) pages 12-14. January 2011. [jada.ada.org](http://jada.ada.org). Accessed Feb. 11, 2011.

THE AUTHOR, Prabu Raman, DDS, MICCMO, LVIM, FPFA, FACD, can be reached at [praman@sbcglobal.net](mailto:praman@sbcglobal.net).

#### OTHER AUTHORS' CRITIQUES, CONTINUED FROM 570

When discussing postural stability, cervical posture and mandibular posture, no mention is made of altered posture due to increased nasal resistance and mouth breathing, which have been shown to significantly affect growth and posture.

In the Dana P. case, the joints are clearly loaded, with greatly reduced joint space. Her improvement could be attributed to the relative decompression of the TMJ and improved airway, breathing and sleep.

The need for physiologic neurologic orthodontics is questionable at age 49. In the AC philosophy, 90 percent of patients are cognitively and behaviorally weaned off appliance wear during the day, avoiding the need for case finishing.

In the data-gathering section, joint auscultation is missing, which is a basic part of joint evaluation, either manually or by stethoscope.

The neuromuscular paradigm popularized by Jankelson focuses primarily on muscle without recognizing the contribution of TMJ and AC in therapeutic treatment.

## Dr. Raman's Response to Critiques

I agree with Dr. Friction that there is no "one-size-fits all" approach to TMD. He states that the three authors besides him "rely on the same general treatment approach — that of primarily correcting the mandibular jaw position through splints." The more one knows, the more one understands the nuances. However, only dentists have the necessary skills to correct mandibular position, which has an enormous impact on the whole body.

Dr. Friction questions the reliability and validity of neuromuscular dentistry bioinstrumentation. That sounds like the oft-repeated canard about "specificity and sensitivity" of these instruments in diagnosing TMD, as though it were a simple condition that could be addressed with a binary answer.<sup>1</sup> With 66 markers of this syndrome, including intraoral signs, headache, neck pain, ear pain, etc., the mathematical possibility of presentations is  $2^{66}$  = over 73 quintillion; ergo the improbability of randomized controlled trials. Bioinstruments measure parameters accurately.<sup>2</sup> The FDA cleared them in 1994 and the ADA accepted them in 1996 because "these products were found to meet the Council's Guidelines for Instruments as Aids in the Diagnosis of Temporomandibular Disorders."<sup>3</sup> Electromyography (EMG) is a

widely used medical diagnostic test. Why is it less valid than digital palpations?

Dr. Gelb appears unaware that physiological neuromuscular dentistry (PNMD) has progressed exponentially on the foundation laid by Dr. Jankelson. The PNMD approach includes achieving unstrained masticatory and cervical musculature, decompressed TMJs and improved airway. The resultant position of the TMJ in the example case demonstrates this point. Doppler and electrosonography were used in the diagnosis of this case but were not included above due to space constraints. Age 49 is not too old to move the teeth to permanently support an optimal jaw/neck position. The patient made an informed choice.

Dr. Simmons raises several good points. EMG provides information that an astute clinician uses along with other data for diagnosis and treatment. While many studies support this,<sup>4</sup> of more importance are the complex cases that were resolved. Palpation is used to augment objective data, not to take its place. He states that "muscles are the alarm" and "neuromuscular dentistry seems to be treating the secondary, not the primary cause of a patient's pain and dysfunction." PNMD treatment consists of

## Looking for C.E.? Do we have a calendar for you.

Sponsor	Course Title	Date(s)	Speaker(s)	Location	Cost	Units
Arthur A. Dugoni School of Dentistry	49th Annual Colonel Allyn D. Burke Memorial Dental Symposium	June 27-28, 2014	TBD	Monterey	\$385 dentist; \$195 allied dental professionals	14
Arthur A. Dugoni School of Dentistry	A Comprehensive Multidisciplinary Overview of Head and Neck Cancer	November 1, 2014	Homer Assisi, DDS; William Carpenter, DDS, MS; Mark Singer, MD; Paul Suber, DDS, SED	San Francisco	\$245 Dentist; \$185 Allied Dental Professionals	6
Arthur A. Dugoni School of Dentistry	Adhesion: The Evolving World of Change	September 27, 2014	Patrick Roetzer, DDS; Troy Schmidding, DDS	San Francisco	\$425 early bird tuition received by Aug 27; \$470 regular tuition	6
Arthur A. Dugoni School of Dentistry	Autogenous Gingival Grafting: The KIWMethod Minimally Invasive Non-palatal Approach	November 15, 2014	George Maripho, DDS	San Francisco	\$433 early bird tuition received by Oct 13; \$493 regular tuition	4
Arthur A. Dugoni School of Dentistry	Bone Grafting, Ridge Preservation and Ridge-Split Procedures for General Practitioners	October 11, 2014	Ian Tolstov, DDS, DMD; Anders Nohrsted, PhD, DDS	San Francisco	\$495 early bird tuition received by Sept 11; \$543 regular tuition	7
Arthur A. Dugoni School of Dentistry	Certification in Radiation Safety for Allied Dental Professionals	September 13, October 4	Elena Francisco, RDH, RDHAP, MS; Eham Mohdavi, DDS	San Francisco	\$685 early bird tuition received by Aug 13; \$750 regular tuition	32
Arthur A. Dugoni School of Dentistry	Dental Wear: It's Not Just About Bruxism	November 13, 2014	Ward Noble, DDS, MS, MSED	San Francisco	\$99	2.5
Arthur A. Dugoni School of Dentistry	Don't Just Inject, Add Some Finesse: Local Anesthesia Workshop	December 6, 2014	Alan Budenz, MS, DDS, MBA; Bernadette Alwaro Fe, DDS	San Francisco	\$443 early bird tuition received by Nov 6; \$490 regular tuition	7

CDA makes it easy to find the courses you need when you need them, and it's simpler than ever at [cda.org/cecalendar](http://cda.org/cecalendar). Whether on laptop, tablet or smartphone, C.E. courses are now listed online and always at your fingertips.



structural corrections so that the “alarms” will be silenced. That includes recapturing displaced disks. The PNMD approach is not either the muscles or the structures or the airway — it includes all of these.

All TMD philosophies, including PNMD, seek pain-free, unstrained muscle balance.<sup>5</sup> I invite everyone to study PNMD. My own journey began 30 years ago, when my wife was diagnosed with disabling migraine as she was completing her four bicuspid extraction orthodontics, including anterior retraction. Refusing to accept that the two were unrelated, I studied work by many mentors, including Drs. John Witzig, Jay Gerber, Robert Jankelson, James Garry, Bill Dickerson and Mariano Rocabado. Not only was I able to relieve her of migraine many years ago, my single practice focus has become helping patients who were given incurable medical diagnoses, with lifelong pain management as the only choice, to actually resolve myriad symptoms from TMD through PNMD. I invite every dentist to explore PNMD through serious study with an open but skeptical mind.

- Cooper BC, Adib F. An Assessment of the Usefulness of Kinesiograph as an Aid in the Diagnosis of TMD: A Review of Manfredin et al.'s Studies. *Crania*, July, 2014. [www.maneyonline.com/doi/abs/10.1179/2151090314Y.0000000010?queryID=34%2F4892191](http://www.maneyonline.com/doi/abs/10.1179/2151090314Y.0000000010?queryID=34%2F4892191).
- Cooper, BC. The role of bioelectronic instruments in documenting and managing temporomandibular disorders. *J Am Dent Assoc* 1996;127:1611-1614.
- American Dental Association, Report on acceptance of TMD devices. ADA Council on Scientific Affairs. *J Am Dent Assoc* 1996;127:1615-1616.
- lynn J, Mazzocco M, Miloser S, Zullo T. Diagnosis and Treatment of Craniocervical Pain and Headache based on Neuromuscular Parameters. *Am J Pain Management* 1992; 2:3, 143-151.; Myslinski, NR, Buxbaum, JD, Parente, FJ. The use of electromyography to quantify muscle pain. *Meth and Find Exptl Clin Pharmacol* 1985; 7(10):551-556.; Sheikholeslam A, Holmgren K, Riise C. A clinical and electromyographic study of the long-term effects of an occlusal splint on the temporal and masseter muscles in patients with functional disorders and nocturnal bruxism. *J Oral Rehabil* 1986; 13:137-145.; Tsolka P, Fenion M, McCulloch A, Preiskel H. Controlled clinical, electromyographic and kinesiographic assessment of craniomandibular disorders in women. *J Orofacial Pain* 1994; 8:80-9.
- Dawson PE. *Functional Occlusion: From TMJ to Smile Design*. St. Louis: Mosby Elsevier, 2006:114-129.